

Prosthetic Management of the Partial Foot Amputation—A Literature Search and New Model

Widely published data show that prosthetic outcomes for PFAs have not been satisfactory, either from a medical outcome or from a patient satisfaction point of view.

BY ROBERT MEIER

Introduction

In June 2021 a post from an O&P practitioner was listed on the O&P list serve¹ asking for recommendations on managing a Chopart amputation. There were an incredible array of answers including:

- (Go to) BKA—don't even waste your time
- Gauntlet style AFO
- ... abbreviated CROW walker
- Custom molded total contact partial foot orthotic / depth inlay shoe with rocker soles
- Matching shoe for the other side with lift
- Gauntlet style AFO with toe filler, made into a walking boot
- SACH heel and rocker bottom on shoe—soft custom-made silicone foot bed
- Clamshell posterior opening and shoe lift on the other side...
- Start with cowboy boots...

Diversity is a good thing, but these comments offer advice that is contradictory and show a complete lack of consensus on how to manage a relatively common level of amputation. The divergent suggestions triggered a literature search to find data or published direction on how to manage the partially amputated foot. Searches were done on *PubMed*

(*Home—PMC—NCBI (nih.gov)*) and *Google Scholar (www.Google Scholar)* with phrases including “Partial Foot Amputation”, “Prosthesis for Partial Foot Amputation”, and “Management of Partial Foot Amputations”.

PFA is significantly greater (about 25 times greater) for people with diabetes. The incidence is (94.24 per 100,000 people with diabetes; 95% CI 55.50 to 133.00) compared to those without (3.80 per 100,000 peo-

There is a complete lack of consensus on how to manage a relatively common level of amputation.

Search Results

The search uncovered numerous studies indicating the risk factors involved in necessitating a partial foot amputation (PFA) including osteomyelitis, peripheral artery disease, chronic kidney disease, ulcer size, and forefoot ulcer location.² Martins-Mendes found that there is an independent contribution of diabetic foot ulcer on lower extremity amputation and mortality risk.³ There are no lack of data on factors leading to PFA.

Nor are there any lack of data on the incidence and prevalence of PFA. In a systematic review to synthesize epidemiological data describing the incidence rate and prevalence of PFA, Dillon et al found that the risk of

ple without diabetes; 95% CI 1.43 to 6.16). The weighted mean annual incidence rate of PFA was 109.63 per 100,000 people with diabetes.⁴

Kaminski found prevalence estimates of 14.4% for foot ulceration and 5.9% for amputation in adults on dialysis.⁵

The trend in surgical interventions is an increase in PFA with a corresponding decrease in trans-tibial amputations. Dillon reports that the incidence of transtibial amputation (TTA) has declined steadily since about the year 2000, and there is some evidence that PFA has increased proportionately.⁶

Wound healing is another area

Continued on page 152

Prosthetic (from page 151)

where data are readily available. In his study, Zhang found that the reported transmetatarsal amputation (TMA) wound healing rates from multiple series were not good (range, approximately 40–70%).⁷ In the same vein, Dillon reports that partial foot amputation is associated with high rates of complications and subsequent transtibial amputation.⁸ No detailed research or analysis was found to identify and define the causes of these complications, other than the assumption that the underlying causes of amputation still exist and may progress post-amputation.

Management of diabetic foot ulcers is broadly covered in literature. Subjects ranging from wearable devices⁹ to nutritional interventions¹⁰ to platelet-rich gel treatment¹¹ to negative pressure wound therapy¹² to telemedicine¹³ were readily found. Absent from this search were any findings that discussed alternatives to managing destructive shearing forces that occur within the PFA foot during walking.

Some make the argument¹ that outcomes of PFAs are so bad that it's better to just go straight to a TTA. In 2014 Quigley reported that there is insufficient evidence about differenc-

on pressure finding that both first ray and TMA amputations lead to higher pressures that could lead to subsequent amputations.¹⁵

The lack of discussion on shearing forces, limb length loss measured from fibular head to floor, or the absence of studies on definitive prosthesis for PFAs is remarkable. In an epic 119-page report, Wang et al listed 50

fibular head to floor acquired limb length discrepancy and by restoring the propulsive lever arm to minimize gait compensatory mechanisms.

Preservation of the residuum involves managing pressure, friction and shearing forces. It must be noted that even with the best possible prosthetic intervention that it is still possible that vascular disease would

No amount of cushioning or padding can resolve shearing forces.

recommendations for managing every aspect of the diabetic foot. There is no mention of prosthetic management for the partially amputated foot.¹⁶ Significantly he did suggest that Achilles tendon lengthening can reduce the risk of recurrence of foot ulcers by 75% in 7 months and 52% in 2 years, especially in patients who present with neuropathic forefoot ulcers complicated by a limited ankle dorsiflexion of $< 5^\circ$.¹⁶

A Biomechanical Approach

The necessity of a fresh look at managing the partially amputated foot became obvious. A comprehen-

progress that would still lead to a more proximal amputation. The goal should be to make sure the prosthetic intervention doesn't contribute to a secondary reamputation.

Limb Preservation

Pressure is simply defined as force over area. With a PFA the area of the foot is decreased so there has to be an increase in pressure. Data provided by Thorud¹⁵ and others confirm that increased pressure can contribute to soft tissue breakdown of the residuum. Pressure on soft tissue can blanch blood from those tissues leading to cell death and eventual ulcer formation. This increase in pressure makes a custom socket or distal cushion of the entire residuum medically necessary to distribute forces over a larger area.

Friction may be the easiest of the potential destructive forces to manage that can impact the viability of the residual foot. Friction is defined as one body moving against another. Poorly fitted footwear or orthotic/prosthetic interventions that are too large can result in friction that leads to disruption of soft tissue, usually in the form of blisters.

Data on shearing forces were not found in this study. These forces are perhaps the most destructive to the residuum and the hardest to control. Consider the foot as a series of lever arms: the forces of the posterior compartment cross the ankle and control the mid- and forefoot lever arms distal to the ankle. Forces from the anterior compartment cross the ankle and control the rearfoot. When the

Continued on page 153

The goal should be to make sure the prosthetic intervention doesn't contribute to a secondary reamputation.

es in quality of life (QoL) between persons with PFA or TTA. Contrary to common belief, the available evidence suggests that QoL may be similar in persons with PFA and TTA.¹⁴ In 2017 Dillon was a bit more pointed. He stated that more distal amputation results in better mobility, improved QoL, and lower mortality. However, PFA has been associated with low rates of healing and complications that often lead to ipsilateral re-amputation. Neither author examined the exact cause of the re-amputations, although increased pressure on soft tissue has been discussed. In 2021 Thorud presented a thorough section

sive model is needed to manage issues that could be contributing to the high failure rates of current methods. The need for a new model is based on widely published data that show that prosthetic outcomes for PFAs were not satisfactory, either from a medical outcome or from a patient satisfaction point of view.

There are two separate but complimentary goals in this model: one is to preserve the residual foot and make sure that the prosthetic intervention doesn't contribute to a subsequent proximal amputation. The second is to restore gait to as close to normal as possible by resolving the

Prosthetic (from page 152)

forefoot is shortened, the power of the calf group overpowers the now too-short residual forefoot lever arm, causing residual bone to move inside the skin, disrupting or shearing connective tissue within the foot. The result of this shearing is the development of calluses. Continued shearing usually results in ulcer formation under the callus, and repetitive ulcer formation usually leads to PFA.

The other consequence of a too-short anterior lever arm is the resultant loss of propulsion. Power crossing the ankle normally propels the foot off the ground. That same power initiates swing during gait. Dillon reported that amputation proximal to the metatarsal heads compromised the normal propulsive function of the foot¹⁷ leading to increased metabolic cost during gait.

Molded plastic AFOs may exacerbate the problem. Vistamehr reports that polypropylene AFOs restrict the ankle range of motion and hinder the generation of propulsion and the regulation of angular momentum in both the frontal and sagittal planes.¹⁸

No amount of cushioning or padding can resolve shearing forces. The only solution to the destructive forces of shearing is to restore the length of the propulsive lever arm. That can be accomplished through the use of a carbon composite AFO that features a full-length footplate and a pre-tibial shell that comes to the height of

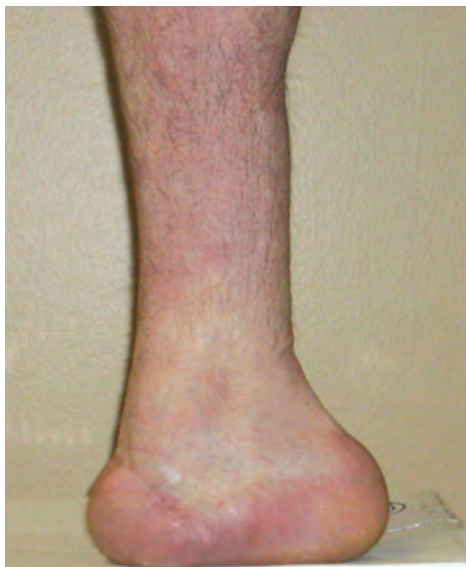

Figure 1: Chopart with 0° CIA, bulbous heel

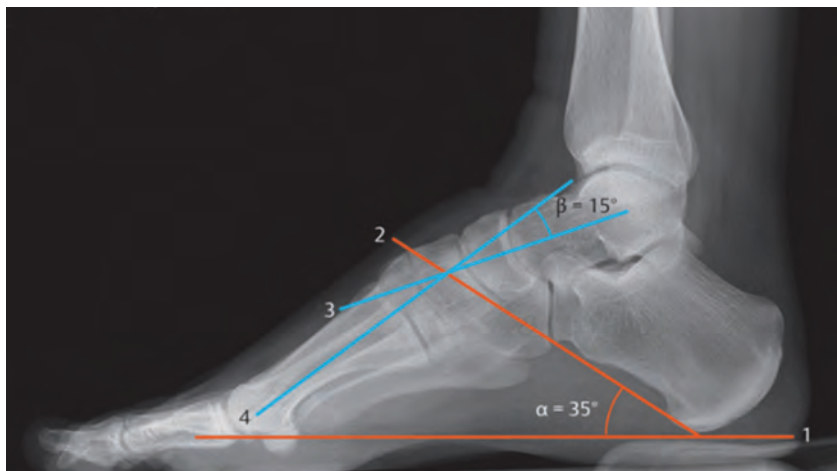


Figure 2: Neutral CIA

Restoring acquired limb length is necessary to help restore pelvic balance and symmetrical gait in the PFA population.

the tibial tubercle. The footplate and lateral strut act like a spring-board at a swimming pool to load potential energy and then return that energy in the form of motion to help restore the propulsive lever arm. Kaib reported that high-profile prostheses with ventral shell are more suitable to re-acquire the lost forefoot lever after Chopart amputation.¹⁹

The same lever arm criteria are required to avoid shearing forces and callus formation on more distal amputations. If callus formation on the distal end of the residuum at any level is an adverse complication that could lead to reamputation, then restoring the length of the propulsive lever arm is the only logical and medically necessary solution.

Gait Restoration

There are two issues that need to be addressed in order to restore gait function in the PFA population. The first is to restore the propulsive lever arm—the same lever arm that helps minimize shearing as described above. Mueller reported that power crossing the ankle becomes negligible with any amputation involving the metatarsal heads.²⁰ The absence of the

anatomical propulsive lever arm leads to proximal compensations including trunk sway, hip hiking, excessive trunk torque, shorter sound side step length and shorter involved side time in single limb stance. Restoring the propulsive lever arm helps minimize compensatory mechanisms and allows the trunk to “go along for a free ride”, making gait more stable and efficient.

Recently Anderson et al published a case study of a bilateral PFA patient with recurrent ulcer formation. After just one week with (carbon composite AFO) prostheses, the patient reported marked improvement in quality of life due to improved walking ability on level and uneven terrain, marked improvement in confidence, and reduced pain.²¹

The second issue to help restore gait is to manage the limb length deficit that is acquired secondary to PFA. The literature search did not find any reference on this subject, but it is commonly seen in clinical practice. The extreme of this presentation occurs with a Chopart amputation where the weightbearing patient presents with a large bulbous heel (Figure 1). The rigid architecture of the mid- and forefoot support the ankle in its

Continued on page 154

THE DIABETIC FOOT

Prosthetic (from page 153)

neutral posture. The loss of that rigid bone structure leads to the ankle dropping into plantarflexion. Because there is no longer a mid- or forefoot to use as reference, the only anatomical reference left to determine ankle neutral is the calcaneus. With the ankle at its neutral posture the neutral calcaneal inclination angle (CIA) is 18° to 35° (Figure 2).²² Lower angles are generally associated with more pronated feet and higher angles are usually associated with more supinated feet.

With the Chopart related bulbous heel now posterior to the tibia instead of underneath it, there has to be a resultant limb length loss associated with that posture. Based on limited clinical experience and physical models, one can anticipate an acquired limb length loss for a Chopart amputation—measured from fibular head to floor—of 2 to 3 cm.

That finding led to discovering if there is also limb length loss associated with more distal amputations. Using physical models and limited clinical findings, there is a high probability of limb length loss with any amputation proximal to the metatarsal heads. A loss of .75 to 1.25 cm can be anticipated with a TMA, while a limb length loss of 1.25 to 1.5 cm can be anticipat-

ed with a Lisfrank amputation. Restoring acquired limb length is necessary to help restore pelvic balance and symmetrical gait in the PFA population.

The proposed prosthetic intervention is designed to manage pressure, friction and most importantly shearing forces to minimize callus and therefore ulcer formation. It is also designed to restore limb length and restore propulsion during gait, thereby minimizing proximal compensations and the metabolic cost of gait.

CIA toward a more neutral posture in the sagittal plane, matching the sound side as much as possible. The posterior aspect can be used to post for excessive calcaneal ROM in the frontal plane just as one would post a foot orthotic.

A prefabricated heavy-duty carbon composite AFO is then prepared by adding an interface liner to the inside of the pretibial shell. The modified socket is then placed on the footplate and aligned to the pretibial

The shoes should be well constructed on a neutral last with as firm a sole material as possible.

Intervention Model

Before creating a custom prosthesis, an assessment is made to determine available ROM at the involved side ankle. That is done by the patient standing unshod on the residuum on the end of a board. The other end is then lifted to determine available ankle ROM (Figure 3). A non-weight-bearing slipper cast or scan is used to capture the residual foot and a positive model is made from that.

It is suggested that the interface liner be contoured over the model using 1/8" material similar to Impression Puff 25 durometer EVA. The "socket", more accurately the "distal cushion", is then formed using 1/8" black co-poly. The plantar anterior aspect of this shell is then posted to restore the

shell so there is equal pressure from top to bottom of the tibia. Once that is established, the filler prosthesis is added to the footplate anterior to the socket using material similar to 1" Microcell Puff® Lite. The prosthesis is then shaped to match the sound side length, width and height (Figure 4).

The prosthesis is placed in the patient's footwear and then they put their shoes on. The shoes should be well constructed on a neutral last with as firm a sole material as possible. Avoid soft cushiony soles as this takes away from the support of the prosthesis and makes gait less stable.

In limited experience many patients will adapt to the prosthesis almost immediately. For others it may take some time—hours or even

Continued on page 155



Figure 4: Custom partial foot prosthesis

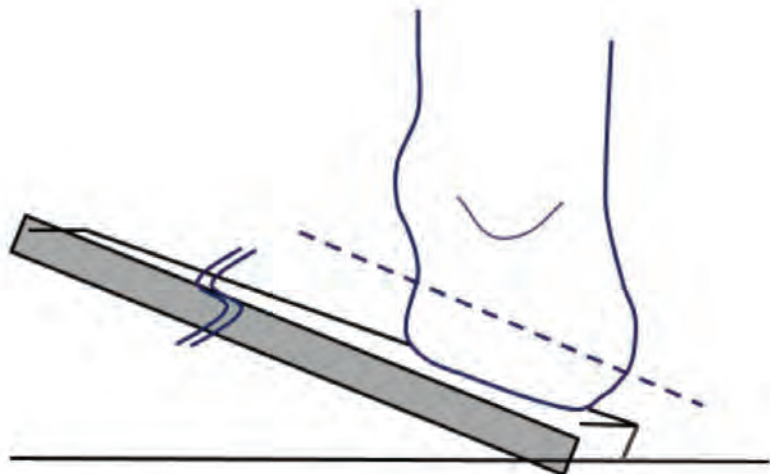


Figure 3: Find available CIA

Prosthetic (from page 154)

days—to acclimate to the new intervention. If the occasional patient has residual gait deviations in the new device, gait training by a physical therapist is sometimes recommended.

Future Research

Future research could focus on designs to study PFA patients who are failing in conventional interventions and who are then switched to this proposed design. The study should include both the medical presentation of the residuum before and 6 weeks after switching and include patient reported outcomes on quality-of-life issues. As few individual clinics see enough patients to gain numbers that are statistically significant, the study could be done to standard protocols by numerous clinics in a larger organization. **PM**

References

- ¹ (OANDP-L@LISTS.UFL.EDU)
- ² Jun Ho Lee,1 Ji Sung Yoon,2 Hyoung Woo Lee,2 Kyu Chang Won,2 Jun Sung Moon,2 Seung Min Chung,3 and Yin Young Lee3. Risk factors affecting amputation in diabetic foot. *Yeungnam Univ J Med.* 2020 Oct; 37(4): 314–320. Published online 2020 May 6. doi: 10.12701/yujm.2020.00129. PMID: PMC7606965 PMID: 32370489
- ³ Daniela Martins-Mendes 1, Matilde Monteiro-Soares 2, Edward John Boyko 3, Manuela Ribeiro 4, Pedro Barata 5, Jorge Lima 6, Raquel Soares 7. The independent contribution of diabetic foot ulcer on lower extremity amputation and mortality risk. *J Diabetes Complications.* Sep-Oct 2014;28(5):632-8. doi: 10.1016/j.jdiacomp.2014.04.011. Epub 2014 Apr 24. PMID: 24877985 PMID: PMC4240944 DOI: 10.1016/j.jdiacomp.2014.04.011
- ⁴ Michael P Dillon, Matthew Quigley, Stefania Fatone. A systematic review describing incidence rate and prevalence of dysvascular partial foot amputation; how both have changed over time and compare to transtibial amputation. *Syst Rev.* 2017 Nov 21;6(1):230. doi: 10.1186/s13643-017-0626-0 PMID: 29162147 PMID: PMC5696800
- ⁵ Michelle R Kaminski 1, Anita Raspo- vic 2, Lawrence P McMahon 3, Katrina A Lambert 4, Bircan Erbas 4, Peter F Mount 5, Peter G Kerr 6, Karl B Landorf. Factors associated with foot ulceration and amputation in adults on dialysis: a cross-sectional observational study. *BMC Nephrol.* 2017 Sep 8;18(1):293. doi: 10.1186/s12882-017-0711-6.
- ⁶ Dillon MP, Quigley M, Fatone S. Outcomes of dysvascular partial foot amputation

and how these compare to transtibial amputation: a systematic review for the development of shared decision-making resources. *Syst Rev.* 2017 Mar 14;6(1):54. doi: 10.1186/s13643-017-0433-7. PMID: 28288686; PMCID: PMC5348872.

⁷ Shanshan Zhang 1, Shumin Wang 2, Lei Xu 2, Yang He 2, Jiali Xiang 2, Zhengyi Tang 3. Clinical Outcomes of Transmetatarsal Amputation in Patients with Diabetic Foot Ulcers Treated without Revascularization. *Diabetes Ther* 2019 Aug;10(4):1465-1472. doi: 10.1007/s13300-019-0653-z. Epub 2019 Jun 26.

⁸ Dillon MP, Anderson SP, Duke EJ, Ozturk HE, Stuckey R. The lived experience of sequential partial foot and transtibial amputation. *Disabil Rehabil.* 2020 Jul;42(15):2106-2114. doi: 10.1080/09638288.2018.1555288. Epub 2019 Jan 22. PMID: 30669884.

⁹ Health Quality Ontario. Fibreglass Total Contact Casting, Removable Cast Walkers, and Irremovable Cast Walkers to Treat Diabetic Neuropathic Foot Ulcers: A Health Technology Assessment. *Ont Health Technol Assess Ser.* 2017 Sep 21;17(12):1-124. PMID: 28989556; PMCID: PMC5628703.

¹⁰ Moore ZE, Corcoran MA, Patton D. Nutritional interventions for treating foot ulcers in people with diabetes. *Cochrane Database Syst Rev.* 2020 Jul 17;7(7):CD011378. doi: 10.1002/14651858.CD011378.pub2. PMID: 32677037; PMCID: PMC7388930.

¹¹ Pu D, Lei X, Leng W, Zheng Y, Chen L, Liang Z, Chen B, Wu Q. Lower limb arterial intervention or autologous platelet-rich gel treatment of diabetic lower extremity arterial disease patients with foot ulcers. *Ann Transl Med.* 2019 Sep;7(18):485. doi: 10.21037/atm.2019.07.87. PMID: 31700921; PMCID: PMC6803174.

¹² Ji S, Liu X, Huang J, Bao J, Chen Z, Han C, Hao D, Hong J, Hu D, Jiang Y, Ju S, Li H, Li Z, Liang G, Liu Y, Luo G, Lv G, Ran X, Shi Z, Tang J, Wang A, Wang G, Wang J, Wang X, Wen B, Wu J, Xu H, Xu M, Ye X, Yuan L, Zhang Y, Xiao S, Xia Z. Consensus on the application of negative pressure wound therapy of diabetic foot wounds. *Burns Trauma.* 2021 Jun 21;9:tkab018. doi: 10.1093/burnst/tkab018. PMID: 34212064; PMCID: PMC8240517.

¹³ Ming A, Walter I, Alhajjar A, Leuckert M, Mertens PR. Study protocol for a randomized controlled trial to test for preventive effects of diabetic foot ulceration by telemedicine that includes sensor-equipped insoles combined with photo documentation. *Trials.* 2019 Aug 22;20(1):521. doi: 10.1186/s13063-019-3623-x. PMID: 31439007; PMCID: PMC6704693.

¹⁴ Quigley M, Dillon MP. Quality of life in persons with partial foot or transtibial amputation: A systematic review. *Prosthet Orthot Int.* 2016 Feb;40(1):18-30. doi: 10.1177/0309364614546526. Epub 2014 Sep

2. PMID: 25185154.

¹⁵ Thorud et al. Conservative care considerations for partial foot amputation in patients with diabetes. *Podiatry Today* March 2021

¹⁶ Wang A, Lv G, Cheng X, Ma X, Wang W, Gui J, Hu J, Lu M, Chu G, Chen J, Zhang H, Jiang Y, Chen Y, Yang W, Jiang L, Geng H, Zheng R, Li Y, Feng W, Johnson B, Wang W, Zhu D, Hu Y. Guidelines on multidisciplinary approaches for the prevention and management of diabetic foot disease (2020 edition). *Burns Trauma.* 2020 Jul 6;8:tkaa017. doi: 10.1093/burnst/tkaa017. PMID: 32685563; PMCID: PMC7336185.

¹⁷ Dillon MP, Barker TM. Preservation of residual foot length in partial foot amputation: a biomechanical analysis. *Foot Ankle Int.* 2006 Feb;27(2):110-6. doi: 10.1177/107110070602700207. PMID: 16487463.

¹⁸ Vistamehr A, Kautz SA, Neptune RR. The influence of solid ankle-foot-orthoses on forward propulsion and dynamic balance in healthy adults during walking. *Clin Biomech (Bristol, Avon).* 2014 May;29(5):583-9. doi: 10.1016/j.clinbiomech.2014.02.007. Epub 2014 Mar 7. PMID: 24698166; PMCID: PMC5893997.

¹⁹ Kaib T, Block J, Heitzmann DWW, Putz C, Alimujaj M, Wolf SI. Prosthetic restoration of the forefoot lever after Chopart amputation and its consequences onto the limb during gait. *Gait Posture.* 2019 Sep;73:1-7. doi: 10.1016/j.gaitpost.2019.06.024. Epub 2019 Jul 1. PMID: 31299498.

²⁰ Mueller, M. J., Salsich, G. B., & Bastian, A. J. (1998). Differences in the gait characteristics of people with diabetes and transtibial amputation compared with age-matched controls. *Gait and Posture, 7(3)*, 200-206. [https://doi.org/10.1016/S0966-6362\(98\)00015-0](https://doi.org/10.1016/S0966-6362(98)00015-0)

²¹ Anderson KM, Evans RE, Connerly CE, Pacha M, Wilken JM. Custom Dynamic Orthoses and Physical Therapist Intervention for Bilateral Midfoot Amputation: A Case Report. *Phys Ther.* 2021 Apr 4;101(4):pzab028. doi: 10.1093/ptj/pzab028. PMID: 33513235; PMCID: PMC8054777.

²² Sahin N, Oztürk A, Atıcı T. Foot mobility and plantar fascia elasticity in patients with plantar fasciitis. *Acta Orthop Traumatol Turc.* 2010;44(5):385-91. doi: 10.3944/AOTT.2010.2348. PMID: 21343689.



Robert Meier is an ABC certified Orthotist. He has specialized in closed chain functional biomechanics and gait for most of his 45-year career, and has earned 6 US patents involving applied biomechanics of the spine and lower extremity.